

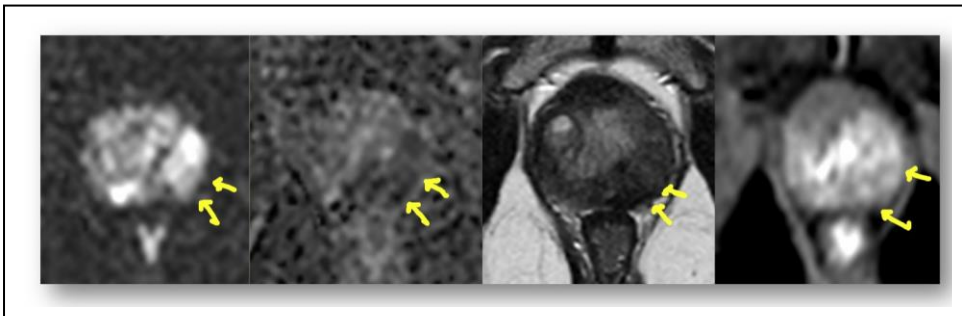
NAME	██████████	AGE / SEX	██████	OPD
REF. BY :	██████████	DATE	██████████	

**MULTIPARAMETRIC MRI PROSTATE**

**Technique:**

A plain and contrast MR of the pelvis was performed using multiplanar sequences with focus on the prostate.

**Findings:**



The prostate is mildly enlarged and measures about 28 ml (4.1 × 3.5 × 4.2 cm × 0.52).

**Peripheral zone:**

There is a large ill-defined T2w hypointense lesion

in the midbody and base level, mainly on the left side with smaller extension to right side. The lesion shows high b-value on DW image and corresponding low signal intensity on the ADC map (ADC ~700 μm<sup>2</sup>/s) (PI-RADS 5). There is mild protrusion on the posterolateral aspect of the capsule and the lesion directly abuts against the left neurovascular bundle.

No other extracapsular spread is seen. The right neurovascular bundles are normal.

**Transition zone:** There are lobulated ill-defined nodular hyperintense and hypointense lesions (PI-RADS 2/3).

Fat planes with respect to rectum are intact.

Urinary bladder: Normal walls with indentation at base by the enlarged prostate.

No pelvic or inguinal adenopathy. No bone lesions.

Upper abdomen screening shows normal liver, gallbladder, biliary tree, pancreas, spleen, both adrenals and kidneys. No upper abdominal adenopathy.

डायरेक्ट कॉन्टेक्ट फॉर MRI डिपार्टमेंट : 0731-2990807, 9285200622

☎ 0731-4970807, 4070807 📞 +91-928-527-0808 | Time: 8 AM to 8 PM ✉ mri@thebiopsy.in  
29 & 21, शांति नगर, केनरा बैंक के ऊपर, श्रीनगर एक्स., खजराना रोड, चन्द्रलोक चौराहे के पास, इन्दौर

NAME		AGE / SEX		OPD
REF. BY :		DATE		

**MULTIPARAMETRIC MRI PROSTATE**

**Remarks:**

In this biopsy proven case of carcinoma of prostate, there is a large hypointense lesion in midbody and base of prostate, with focal capsular bulge along left postero-lateral aspect and abutment against the left neurovascular bundle, corresponding to PI-RADS 5, as described above.

No pelvic or abdominal adenopathy. No bone lesions.

**DR. RAJESH KUMAR GUPTA**

DNB, DMRE, MNAMS, MSIVR

Sr. Consultant; Cross-sectional Clinical  
Radiology (CT & MRI) and Interventions

Typographical errors is regretted in case of doubt please contact us for corrections.

Transcribed by: AB

डायरेक्ट कॉन्टेक्ट फॉर MRI डिपार्टमेंट : 0731-2990807, 9285200622

☎ 0731-4970807, 4070807 📞 +91-928-527-0808 | Time: 8 AM to 8 PM ✉ mri@thebiopsy.in

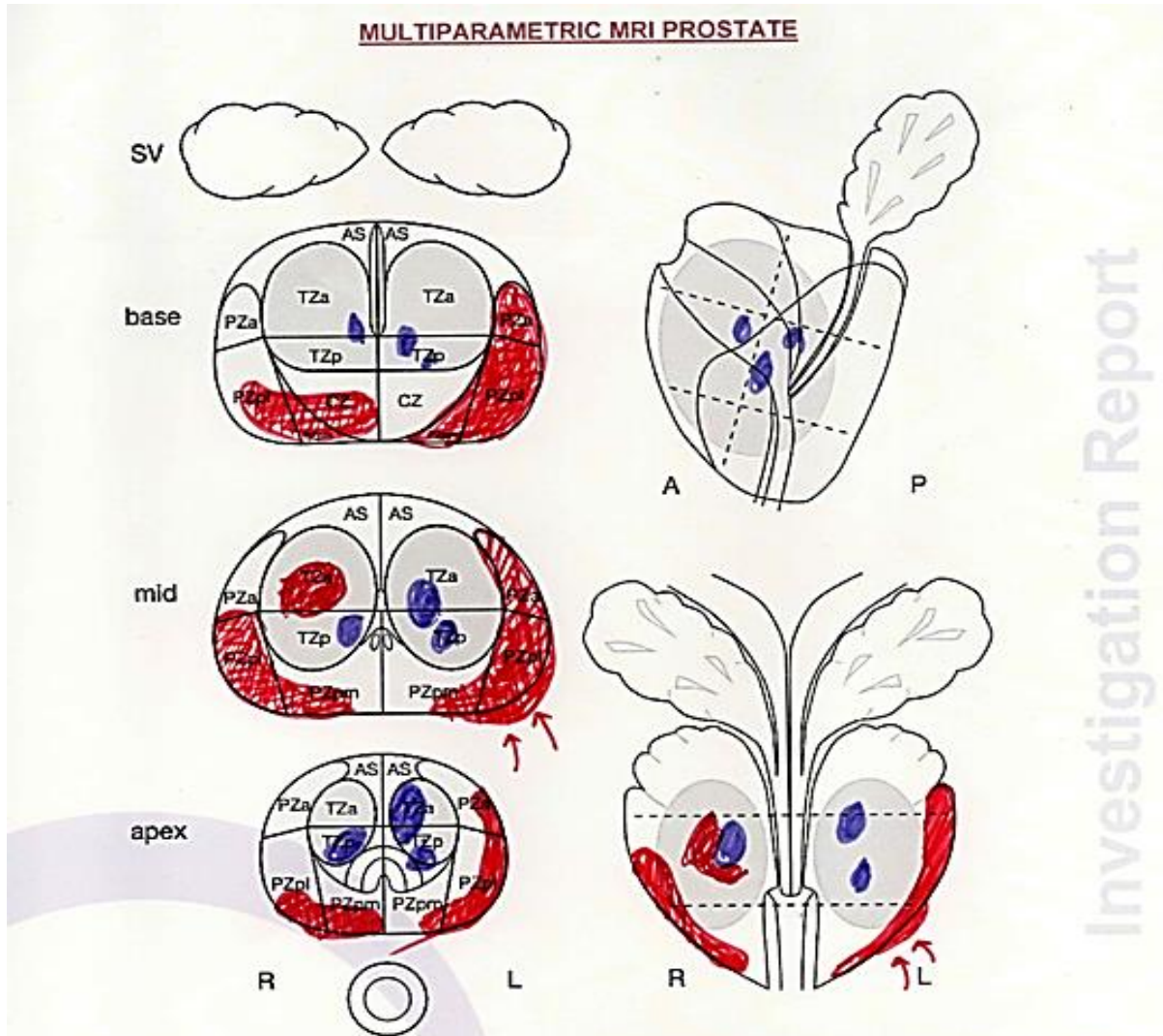
29 & 21, शांति नगर, केनरा बैंक के ऊपर, श्रीनगर एक्स., खजराना रोड, चन्द्रलोक चौराहे के पास, इन्दौर



NAME		AGE / SEX		OPD
REF. BY :		DATE		

**MULTIPARAMETRIC MRI PROSTATE**

MULTIPARAMETRIC MRI PROSTATE



Investigation Report

*Smiles*

**DR. RAJESH KUMAR GUPTA**  
 DNB, DMRE, MNAMS, MCh, FR  
 Sr. Consultant, Cross-sectional Clinical  
 Radiology (CT & MRI) and Interventions  
 Typographical errors is regretted in case of doubt please contact us for corrections.

[●] PI-RADS - 5 Lesions  
 [●] PI-RADS - 4 Lesions

Transcribed by: SG

डायरेक्ट कॉन्टेक्ट फॉर MRI डिपार्टमेंट : 0731-2990807, 9285200622

☎ 0731-4970807, 4070807 📞 +91-928-527-0808 | Time: 8 AM to 8 PM ✉ mri@thebiopsy.in  
 29 & 21, शांति नगर, केनरा बैंक के ऊपर, श्रीनगर एक्स., खजराना रोड, चन्द्रलोक चौराहे के पास, इन्दौर